
Two lower deciduous molars from Mousterian layers of the Grotte du Bison (Arcy-sur-Cure, Yonne, France): an intriguing case of cervical tooth lesion in a Neanderthal child

À propos de deux molaires déciduales inférieures provenant des niveaux moustériens de la Grotte du Bison (Arcy-sur-Cure, Yonne, France) : un exemple de lésion cervicale inédite chez un enfant néanderthalien

Anne-Marie Tillier, Maurice Hardy, Francine David, Michel Girard and Vladimir d'Iatchenko



Electronic version

URL: <http://journals.openedition.org/paleo/2870>

DOI: 10.4000/paleo.2870

ISSN: 2101-0420

Publisher

SAMRA

Printed version

Date of publication: 15 December 2013

Number of pages: 271-278

ISSN: 1145-3370

Electronic reference

Anne-Marie Tillier, Maurice Hardy, Francine David, Michel Girard and Vladimir d'Iatchenko, « Two lower deciduous molars from Mousterian layers of the Grotte du Bison (Arcy-sur-Cure, Yonne, France): an intriguing case of cervical tooth lesion in a Neanderthal child », *PALEO* [Online], 24 | 2013, Online since 16 September 2015, connection on 07 July 2020. URL : <http://journals.openedition.org/paleo/2870> ; DOI : <https://doi.org/10.4000/paleo.2870>

This text was automatically generated on 7 July 2020.



PALEO est mis à disposition selon les termes de la licence Creative Commons Attribution - Pas d'Utilisation Commerciale - Pas de Modification 4.0 International.

Two lower deciduous molars from Mousterian layers of the Grotte du Bison (Arcy-sur-Cure, Yonne, France): an intriguing case of cervical tooth lesion in a Neanderthal child

À propos de deux molaires déciduales inférieures provenant des niveaux moustériens de la Grotte du Bison (Arcy-sur-Cure, Yonne, France) : un exemple de lésion cervicale inédite chez un enfant néanderthalien

Anne-Marie Tillier, Maurice Hardy, Francine David, Michel Girard and Vladimir d'Iatchenko

Firstly, we wish to thank François de La Varende for regular authorizations to excavate at the Grotte du Bison. A.-m. Tillier extends thanks to Y. Delbos and P. Rouas (Odontology faculty, Université Bordeaux 2) for the fruitful discussions they had together. The manuscript was improved by the attentive reading of anonymous experts. Lastly, the kindly contributions of P. Courtaud (UMR 5199) and G. Devilder (UMR 5133) greatly enhanced the quality of the illustrations.

Introduction

- 1 Studies of dentition in Paleolithic children have increased considerably over the past few years and aim to identify significant differences between Neanderthals and anatomically modern humans. These analyses focus mainly on the morphological criteria of the occlusal surface (eg. Bailey 2002; Bailey and Hublin 2006), on the construction time of deciduous and permanent teeth (eg. Ramirez-Rossi and Bermudez

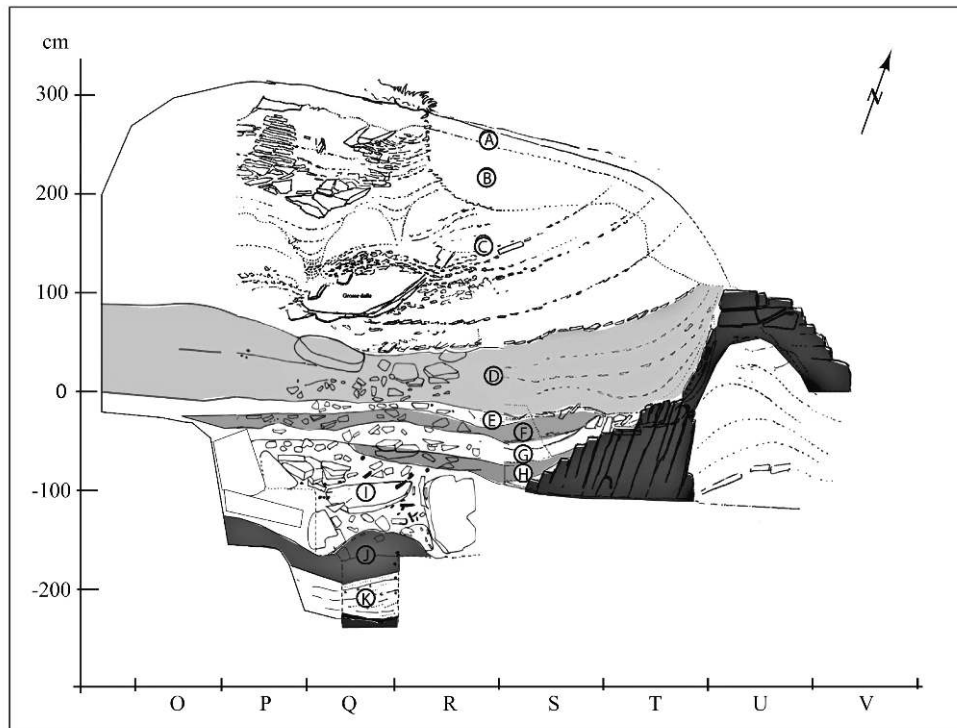
de Castro 2004), or on the microstructure of the teeth and the distribution of the dental crown tissues (eg. Machiarelli et al. 2007; Bayle et al. 2009; Crèvecoeur et al. 2010).

- 2 For the more specific case of lower deciduous molars, several criteria related to the contour of the crown in the occlusal view (ovoid shape with a bucco-lingual tightening of the cusps) and to the structure of the occlusal surface itself, have been advanced to characterize Neanderthal teeth, such as a development of the anterior fovea, the presence of a continuous enamel crest linking the protoconid to the metaconid ("substantial mid-trigonid crest", according to Bailey and Hublin 2006 - p. 505).
- 3 However, the presence of a continuous crest on the second Neanderthal molar does not seem to be a constant characteristic, as shown for example in France, by the fossils from Chateaufort 2 (Tillier 1979), Roc de Marsal (Madre-Dupouy 1992, pers. observation) or La Chaise 13 and 14 (Tillier and Genet-Varcin 1980). On the latter, a mesio-distal groove divides this transversal crest and this configuration is also present on other Middle Paleolithic teeth, such as the first modern children from Qafzeh (Tillier 1999).
- 4 The study of the two deciduous molars from the Grotte du Bison should enable us to place them within the range of known variability and to detect the possible presence of anomalies or pathological traits.

History and archaeological context

- 5 The Arcy-sur-Cure caves (Yonne) have been subjected to many interventions since the 19th century and have provided considerable archaeological and anthropological documents relating to the Upper and Middle Paleolithic and to the transition between these two periods (eg. Leroi-Gourhan A. 1950, 1958, 1961; Leroi-Gourhan Arl. and A. 1964; Baffier and Girard 1997; David et al. 2007, 2009). Programmed excavations in the Grotte du Bison since 1995 have led to the identification of several levels of human occupation (fig. 1), from the final Chatelperronian (level D, dated between $34\,050 \pm 750$ and $33\,670 \pm 450$ years B.P.) to the Mousterian with layers E to J (David et al. 2007, 2009). Layers E and F contain a final Mousterian debitage (dated between $38\,400 \pm 1600$ and $40\,200 \pm 1500$ years B.P.) with habitat and hearth structures, whereas layers G and H yielded a Mousterian with denticulates that can be attributed to isotopic stage OIS 4 (David et al. op.cit.). No absolute dating is available, as of yet, for these last two layers, or for the underlying layer I linked to the Mousterian base horizon (Lhomme in David et al. 2007).
- 6 Over the past few years, layer I has yielded several fragmentary human remains, including some bearing traces of carnivore activity, the latter being regular visitors to the cave (David et al. 2009; Tillier et al. 2013). Two new human teeth (BIS-I S6-2 and BIS I Q5.1), unearthed in 2012, (Hardy et al. 2012) complete the already published anthropological documentation. In this paper, they are compared to the other Mousterian teeth known in Europe, as well as to the only deciduous tooth of the same rank (specimen 29 issued from layer Xb2) which comes from the Chatelperronian level of the Grotte du Renne at Arcy sur- Cure (Bailey and Hublin 2006).

Figure 1 - The Grotte du Bison: stratigraphy of the anterior section (redrawn by G. Devilder) with the location of layer I where the teeth were found.



Estimate of the age at death of the children represented by BIS-I S6-2 and BIS I Q5.1.

- 7 The tooth BIS-I S6-2 is a second lower right deciduous molar (fig. 2). The crown is complete and root edification (fig. 2a) corresponds to stage R3/4 defined by Moorrees et al. (1963), or to stage F of Liversidge and Molleson (2004). The mesial and distal surfaces do not present any contact facet with the adjacent teeth. According to reference criteria issued from the study of extant populations, the age of the child to whom this tooth belongs can be estimated at 3.12 ± 0.26 years, using the Liversidge and Molleson (2004) formulae.
- 8 The tooth BIS I Q5.1 is also a second lower right deciduous molar (fig. 3). The two mesial and distal roots have begun their resorption, and this process is more advanced for the first tooth (fig. 3a). The degree of attrition of the occlusal surface is accompanied by the exposure of lenses of dentine at the cusps. The presence of a clear contact facet on the distal surface of the crown shows that the first permanent molar was functional. The age of the child to whom this tooth belonged can be estimated between 8 and 10 years, according to data from extant populations.
- 9 The new lower deciduous molars from the Grotte du Bison, are two right teeth and thus cannot be from the same child. Moreover, the different stages of edification also prove that they are from two distinct children.

Figure 2 - Right lower second deciduous molar (BIS-I S6-2) from La Grotte du Bison: (a) buccal and (b) occlusal views.

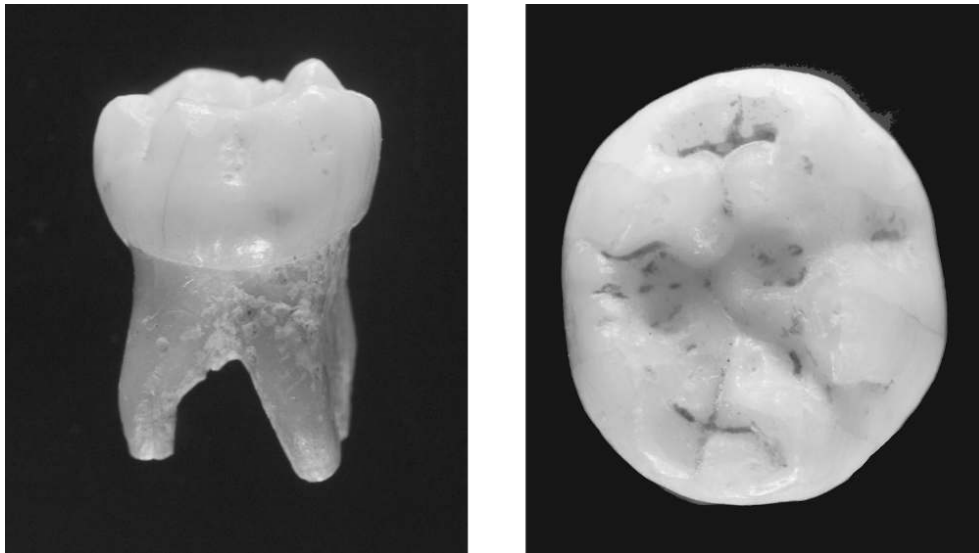
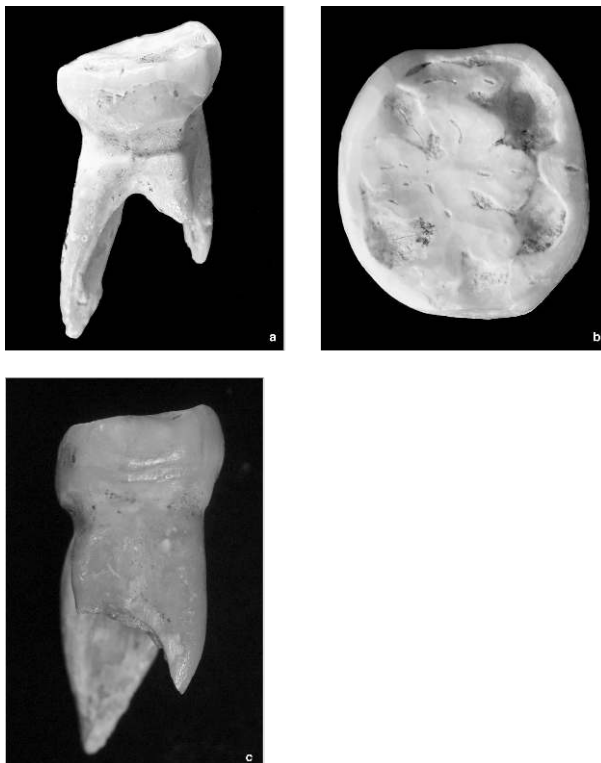


Figure 3 - Lower right deciduous second molar (BIS I Q5.1) from La Grotte du Bison: (a) buccal (b) occlusal and (c) mesial views.



Morphological characteristics of the deciduous molars

1 - BIS-I S6

- 10 The crown of the tooth BIS-I S6 is approximately rectangular-shaped and the configuration of the occlusal surface is easy to identify (fig. 2b). It is a classic

configuration with five cusps, three of which are buccal and two lingual, and the distribution shows no signs of bucco-lingual tightening. The decreasing order of size of these cusps is the following: protoconid and metaconid, hypoconid and entoconid, hypoconulid. The two mesial cusps, the protoconid and the metaconid, are linked by a crest which is interrupted in the middle by a small sagittal groove; this crest delimits a narrow anterior fovea. The central fovea is vast and we note the presence of two grooves running down the buccal side which separate the buccal cusps from each other. The protoconid and metaconid are mesio-distally aligned but a disconnection is observed with the reduced and lingually offset bucco-distal cusp.

2 - BIS I Q5.1

- 11 Due to the wear of the tooth, the crown of the second deciduous molar, BIS I Q5.1, is broadly square-shaped (fig. 3b). Given the development of a contact facet on the distal surface, the location of the bucco-distal cusp (hypoconulid) is diminished. Four dentine lenses, two of which are mesio-distally aligned and two bucco-lingually aligned, are present and correspond to the four main cusps with an almost equivalent degree of wear. No relief can be discerned on the occlusal side as the central fovea has also been eroded.

3 - Comparative data

- 12 From a morphological point of view, the number of cusps and the presence of a transversal crest delimiting the anterior fovea on the occlusal surface of the two deciduous molars from the Grotte du Bison, are not fundamentally different from those of other teeth identified as Neanderthals from the European Paleolithic (Middle and Upper). The layout of the clear transversal crest on the unworn molar BIS-I S6 shows a discontinuous path which recalls the disposition of other Neanderthal teeth (such as Roc de Marsal, La Chaise 13 and 14, Chateaufort 2 for example), thus diverging from the layout cited as the most frequent in the Neanderthal population (Bailey and Hublin 2006).
- 13 A comparison with the molar from the Grotte du Renne (29-Xb2 C8) enables us to discern several additional traits which differentiate the tooth from the Grotte du Bison: the latter does not present a bucco-lingual tightening of the cusps (described on the tooth 29-Xb2 C8 by Bailey and Hublin 2006). On the molar from the Grotte du Bison, only the bucco-distal cusp (hypoconulid) is in a more internal position and its size is reduced compared to the tooth of comparison; there is no sixth cusp and lastly, the occlusal surface is less secondarily subdivided.
- 14 Due to this latter trait, the tooth also diverges from the Chatelperronian molar of equivalent status from the Grotte du Renne which comes from a younger child aged between 7 and 15 months (according to Bailey and Hublin 2006). On this latter tooth, secondary grooves which complexify the occlusal surface are observable.

Crown dimensions and comparison

- 15 The crown dimensions of the two lower deciduous second molars from the Grotte du Bison, as shown in table 1, fit into known Neanderthal variation values (regardless of

the period), as well as into those for Upper Paleolithic teeth. It is noteworthy that the crowns are both rather bucco-lingually narrow, like the Chatelperronian tooth from the Grotte du Renne (29-Xb2 C8). The slight difference in size of the mesio-distal diameter recorded between the two teeth from the Grotte du Bison can be explained by the presence of a wear facet on the distal surface of the molar BIS-I-Q5-1.

Table 1 - Dimensions in mm of the tooth crowns (lower deciduous second molars) from the Grotte du Bison (MD: mesio-distal length; BL: bucco-lingual breadth) and comparison with Paleolithic teeth in Europe. Comparative data from (1) Bailey and Hublin 2006, (2) Tillier et al. 2003, (3) Hillson and Trinkaus 2002, (4) Benazzi et al. 2010, (*) Upper Paleolithic and extant children

	MD	BL
Grotte du Bison I S6	10.0	8.7
Grotte du Bison I Q5.1	9.5	8.6
Grotte du Renne 29 Xb2 C8 droite (1) <i>Châtelperronien</i>	10.0	8.9
Néanderthaliens (2) <i>Moustérien</i>	10.3 ± 0.6 (N=15)	9.3 ± 0.4 (N=15)
Enfants modernes <i>Paléolithique supérieur</i> (3)	10.3 ± 0.7 (N=5)	9.3 ± 0.7 (N=13)
Enfants modernes* (N= 18) (4)	moyenne = 9.93 écart-type = 0.51	moyenne = 8.68 écart-type = 0.42

Paleopathological aspects and anomalies

1 - Carious lesions, enamel hypoplasia

- 16 According to the specialized literature, the frequency of carious lesions would appear to be limited on Middle Paleolithic teeth from Eurasia (Sognnaes 1956; Boydston, Trinkaus, Vandermeersch 1988; Tillier et al. 1995; Trinkaus, Smith, Lebel 2000; Trinkaus and Pinilla 2009; Tillier and Sansilbano-Collilieux 2010). Taking into consideration the geographic distribution of the affected fossils, which are spread over the Mediterranean coastline (southeast France and Israel), some authors (Trinkaus and Pinilla, ibidem) have suggested that the presence of caries may be linked to a diet with a higher carbohydrate content, connected to the faunal composition, which the authors referred to as a “general absence of cold climate fauna in the archaeological assemblage” (2009, p. 74). To our knowledge, for Europe and the Neanderthals, there is only one deciduous molar from the Bau de l'Aubesier with caries (Trinkaus et al. 2000). The new deciduous molars from the Grotte du Bison, like those described earlier at the Grotte du Renne (Bailey and Hublin 2006) are exempt from carious lesions.
- 17 Teeth can also bear linear enamel hypoplasia on the external crown surface, considered as non-specific stress indicators. The etiology of this hypoplasia remains controversial among authors (eg. Goodman and Rose 1990; Neiburger 1990; Schultz et al. 1998), particularly with regard to the possible role of nutritional deficiencies. Investigations carried out on Upper Pleistocene fossils from Europe in relation to the presence of enamel hypoplasia (beyond linear hypoplasia alone) show variable frequencies according to the different authors (eg. Ogilvie et al. 1989; Brennan 1991; Berti and Mahaney 1992; Garcia Sanchez et al. 1994; Skinner 1996; Guatelli-Stenberg et al. 2004), depending on the type of hypoplasia considered. A low percentage including all types

of hypoplasia was recorded for Neanderthal deciduous teeth (3.3%). Neither of the two new teeth from the Grotte du Bison presents enamel hypoplasia, regardless of the category taken into consideration. This observation is in keeping with that already formulated for other deciduous teeth from the two caves of Arcy-sur-Cure, the Grotte du Renne (Bailey and Hublin 2006) and the Grotte du Bison (Tillier et al. 2013).

2 - Cervical lesion affecting the molar BIS I Q5.1

- 18 The tooth BIS I Q5.1 can be distinguished by the presence of a loss of substance all along the buccal side and also very partially along the mesial side (fig. 3a and c) of the cervical region. This lesion presents the aspect of a widened, smooth-based groove. The resulting disconnection at the tooth neck is clearly visible on a mesial view of the tooth (fig. 3c). This type of abrasive lesion has never been described on deciduous Neanderthal teeth. Can this surface alteration be assimilated to a myololysis? And if so, what could have caused it?
- 19 In the specialized literature, the presence of lesions of abrasion at the neck of the tooth (including the Non carious Cervical Tooth Lesions or NCCLs) has only been described in permanent teeth in extant populations. As they are not of bacterial origin, they would present different shapes and forms depending on the degree of abrasion; a narrow depression, a spherical lesion or a wedge-shape for severe cases. Their etiology still seems to be poorly defined (eg. Levitch et al. 1994; Grippo, Simring, Coleman 2012): chemical factors of diverse origins, biomechanical constraints linked to a possible malocclusion (associated in particular with a “tooth flexure” or tooth angulation), intensive tooth brushing, occlusal stress, possibly bruxism are some of the causes cited in the appearance of these lesions. An absence of NCCLs in the archaeological collections from the Copper Age and the Middle Ages in the South of France was connected to the diet, lifestyle (absence of intensive tooth cleaning for example), even to a different dental structure (Aubry et al. 2003).
- 20 In conclusion, the surface modification observed on the molar BIS I Q5.1 from the Grotte du Bison appears to be unique as it affects a milk tooth. It would also represent an exception among Neanderthal deciduous teeth. In the absence of comparative elements, the interpretation of this modification remains delicate, even though a strictly taphonomic cause can be ruled out. The extension of the depression on the buccal surface of the cervical region of the tooth, as well as its smooth and regular aspect would tend to point towards an example of a non-carious cervical lesion, even though this type of lesion has never been described on milk teeth before. However, could a biomechanical cause, or a specific activity during the life of the individual be compatible with the young age of death of the child, between 8 and 10 years? The etiology of this lesion, identified here for the first time on a deciduous tooth, and moreover on a Neanderthal tooth, thus raises questions on several different levels.

BIBLIOGRAPHY

- AUBRY M., MAFART B., DONAT B., BRAU J.J. 2003 - Brief Communication. Study of Non Carious Cervical Tooth lesions in samples of Prehistoric, Historic and Modern Populations from the South of France. *American Journal of Physical Anthropology*, 121, p.10-14.
- BAFFIER D., GIRARD M. 1997 - Le karst d'Arcy-sur-Cure (Yonne) et ses occupations humaines, *Quaternaire*, v. 8, p. 245-255.
- BAILEY S.E. 2002 - *Neandertal Dental Morphology: implications for Modern Human Origins*. PhD Dissertaion, Arizona Sate University, 238 p.
- BAILEY S.E., HUBLIN J.-J. 2006 - Dental remains from the Grotte du Renne at Arcy-sur-Cure (Yonne). *Journal of Human Evolution*, 50, p. 485-508.
- BAYLE P., BRAGA J., MAZURIER A., MACCHIARELLI R. 2009 - Dental development pattern of the Neanderthal child from Roc de Marsal : a high-resolution 3D analysis. *Journal of Human Evolution*, 56, p. 66-75.
- BENAZZI S., FORNAI C., BAYLE P., COQUERELLE M., KULLMER O., MALLEGNI F., WEBER G.W. 2011 - Comparison of dental measurement systems for taxonomic assignment of Neanderthal and modern human lower deciduous molars. *Journal of Human Evolution*, 61, p. 320-326.
- BERTI PR., MAHANEY MC. 1992 - Quantification of the confidence interval of linear enamel hypoplasia chronologies. In: LL. Capasso & AH. Goodman (Eds) *Recent Contributions to the study of Enamel Developmental defects*. Journal of Paleopathology Monogr. Publ.2, Chieti (Italy), p. 19-30.
- BOYDSTUN S. B., TRINKAUS E., VANDERMEERSCH B. 1988 - Dental caries in the Qafzeh 3 early modern human. *American Journal of Physical Anthropology*, 75, abstract, p. 188-189.
- BRENNAN M.U. 1991 - *Health and disease in the Middle and Upper paleolithic of Southwestern France*. PhD Dissertation, New York University.
- CRÈVECOEUR I., BAYLE P., ROUGIER H., MAUREILLE B., HIGHAM T., VAN DER PLICHT J., DE CLERK N., SEMAL P. 2010 - The Spy VI child: a newly discovered Neandertal infant. *Journal of Human Evolution*, 59, p. 641-656.
- DAVID F., D'IATCHENKO V.I., ENLOE J.E., GIRARD M., HARDY M., LHOMME V., ROBLIN-JOUVE A. 2007 - Arcy-sur-Cure (Yonne) - Grotte du Bison ; *Compte-rendu des travaux 2005-2007*, Dijon, Service Régional de l'Archéologie de Bourgogne, novembre 2007, 60 p.
- DAVID F., D'IATCHENKO V.I., ENLOE J.E., GIRARD M., HARDY M., LHOMME V., ROBIN-JOUVE A., TILLIER A.-M., TOLMIE C. 2009 - New Neandertal remains from the Grotte du Bison at Arcy-sur-Cure, France. *Journal of Human Evolution*, 57, p. 805-809.
- GARCIA SANCHEZ M., TILLIER A.-m, GARRALDA MD. VEGA-TOSCANO G. 1994 - Les dents d'enfant des niveaux moustériens de la Grotte de Carihuela (Grenade, Espagne). *Paleo*, 6, p. 79-88.
- GOODMAN A.H., ROSE J.C. 1990 - Dental enamel hypoplasias as indicators of nutritional status. *Yearbook of Physical Anthropology*, New York, Wiley Liss, p. 279- 293.
- GRIPPO J.O., SIMRING M., COLEMAN T.A. 2012 - Abfraction, Abrasion, Biocorrosion, and the Enigma of Non carious Cervical Lesions: a 20-year Perspective. *Journal of Esthetic and Restorative Dentistry*, 24, 1, p. 10-23.

- GUATELLI-STENBERG, D., LARSEN, CS., HUTCHINSON, DL. 2004 - Prevalence of the duration of Linear enamel hypoplasia: a comparative study of Neandertals and Inuit foragers. *Journal of Human Evolution*, 47, p. 65-84.
- HARDY M., DAVID F., d'IATCHENKO V., GIRARD M., ROBLIN-JOUVE A. 2012 - Arcy-sur-Cure (Yonne). Grotte du Bison. Comptes Rendus des travaux 2012. Service Régional de l'Archéologie de Bourgogne, Dijon, 91 p.
- HILLSON S.W., TRINKAUS E. 2002 - Comparative Dental Crown Metrics. In; J. Zilhao and E. Trinkaus, (Eds), *Portrait of the Artist as a Child. The Gravettian Human Skeleton from the Abrigo do Lagar Velho and its archaeological context*. Trabalhos de Arqueologia 22, Lisboa, p. 356-364.
- LEROI-GOURHAN A. 1950 - La Grotte du Loup, Arcy-sur-Cure (Yonne). *Bulletin de la Société Préhistorique Française*, t. XXXVII, n° 5, p. 268-280.
- LEROI-GOURHAN A. 1958 - Étude des restes humains fossiles provenant des Grottes d'Arcy-sur-Cure. *Annales de Paléontologie*, 44, p. 87-148.
- LEROI-GOURHAN A. 1961 - Les fouilles d'Arcy-sur-Cure (Yonne), *Gallia Préhistoire*, t. IV, p. 3-16.
- LEROI-GOURHAN Arl., LEROI-GOURHAN A. 1964 - Chronologie des Grottes d'Arcy-sur-Cure (Yonne). *Gallia Préhistoire*, t.7, p.1-64.
- LEVITCH L.C., BADER J.D., SHUGARS D.A., HEYMANN H.O. 1994 - Non carious cervical lesions. *Journal of Dentistry*, 22, p. 195-207.
- LIVERSIDGE H.M., MOLLESON T. 2004 - Variation in Crown and Root Formation and Eruption of Human Deciduous Teeth. *American Journal of Physical Anthropology*, 123, p. 172-180.
- MACHIARELLI R., MAZURIER A., VOLPATO V. 2007 - L'apport de nouvelles technologies à l'étude des Néandertaliens. In : B. Vandermeersch, B. Maureille (Eds.), *Les Néandertaliens. Biologie et Cultures*. Editions du C.T.H.S., Paris, p. 169-179.
- MADRE-DUPOUY M. 1992 - *L'enfant du Roc de Marsal. Etude analytique et comparative*. Cahiers de Paléanthropologie, Editions du CNRS, Paris, 300 p.
- MOORREES C.F.A., FANNING E. A. & HUNT E. E. 1963 - Formation and Resorption stages of Three Deciduous Teeth in Children. *American Journal of Physical Anthropology*. 21, p. 99-108.
- NEIBURGER E. 1990 - Enamel hypoplasias: poor indications of dietary stress. *American Journal of Physical Anthropology*, 82, p. 231-232.
- OGILVIE M. D., CURRAN B. K., TRINKAUS E. 1989 - The incidence and patterning of dental enamel hypoplasias among the Neandertals. *American Journal of Physical Anthropology*, 79, p. 25-41.
- RAMIREZ-ROSSI F.V., BERMUDEZ DE CASTRO J.M. 2004 - Surprisingly rapid growth in Neandertal. *Nature*, 428, p. 936-939.
- SCHULTZ M., CARLI-THIELE P., SCHMIDT-SCHULTZ T.H., KIEDORF U., KIEDORF H., TEEGEN W-R., KREUT K. 1998 - Enamel Hypoplasias in Archaeological Skeletal remains. In : KW. Alt, FW. Rösing & M. Tescher-Nicola (Eds.). *Dental Anthropology. Fundamentals, Limits and Propects*. Springer Wien New York, p. 293-312.
- SKINNER M. 1996 - Developmental Stress in Immature Hominines from Late Pleistocene Eurasia: Evidence from enamel Hypoplasia. *Journal of Archaeological Science*, 23, p. 833-852.
- SOGNNAES R.F. 1956 - Histological Evidence of Developmental Lesions in Teeth originating from Paleolithic, Prehistoric and Ancient Man. *American Journal of Pathology*, 32, p. 547-577.

TILLIER A.-m 1979 – La dentition de l'enfant moustérien Châteauneuf 2 découvert à Hauteroche (Charente). *L'Anthropologie*, 83/3? 417-438.

TILLIER A.-m 1999 - *Les enfants moustériens de Qafzeh. Interprétation phylogénétique et paléoaurologique*. Cahiers de Paléanthropologie, CNRS Editions, Paris.

TILLIER A.-m, ARENSBURG B., RAK Y., VANDERMEERSCH B. 1995 - Middle Palaeolithic dental caries: new evidence from Kebara (Mount Carmel, Israel). *Journal of Human Evolution*, 29, p. 189-192.

TILLIER A.-m, ARENSBURG B., VANDERMEERSCH B., CHECH M. 2003 - New Human remains from Kebara Cave (Mount Carmel). The place of the Kebara hominids in the Levantine Mousterian Fossil Record. *Paléorient*, 29- 2, p. 35- 62.

TILLIER A.-m, GENET-VARCIN E. 1980 - La plus ancienne mandibule d'enfant découverte dans le gisement de La Chaise de Vouthon (Abri Suard), Charente, France. *Zeischrift. fur Morphologie und Anthropologie*, 71/2, p. 196-214.

TILLIER A.-m, SANSILBANO-COLLILIEUX M. 2010 - Early Hunter-gatherers and Oral health. Inferences from Middle Palaeolithic hominids in Southern Levant. *7ICAANE, London, Programme and Abstract Handbook*, p. 157.

TILLIER A.-m, SANSILBANO-COLLILIEUX M., DAVID F., ENLOE J.G., GIRARD M., HARDY M., D'IATCHENKO V., ROBLIN-JOUVE A., TOLMIE C. 2013 - Les vestiges néanderthaliens provenant des niveaux moustériens de la Grotte du Bison à Arcy-sur-Cure (Yonne). *Bulletins et Mémoires de la Société d'Anthropologie de Paris*, 1-2, p. 39-54.

TRINKAUS E., SMITH R.J., LEBEL S. 2000 – Dental caries in the Aubesier 5 Neandertal Primary Molar. *Journal of Archaeological Science*, 27, p. 1017-1021.

TRINKAUS E., PINILLA B. 2009 - Dental Caries in the Qafzeh 3 Middle Paleolithic Modern Human. *Paléorient*, 36/1, p. 69-76.

ABSTRACTS

At the Grotte du Bison (Arcy-sur-Cure, Yonne), the geological sequence includes seven levels of human occupations from the Mousterian (Middle Palaeolithic) to the Châtelperronian (Early Upper Palaeolithic). Recent excavations have led to the discovery of few neanderthal human remains in Mousterian layers J and I (David *et al.* 2007 ; Tillier *et al.* 2013). Two additional deciduous lower molars were found in layer I during the 2012's season. These new anthropological finds add to our knowledge about the authorship of final Middle Palaeolithic industries in north-eastern France. One of the teeth shows a non-carious cervical lesion, unknown in children, which raises the question of its etiology.

La Grotte du Bison (Arcy-sur-Cure, Yonne) a livré une séquence de sept niveaux d'occupation humaine allant du Paléolithique moyen (Moustérien) au début du Paléolithique supérieur (Châtelperronien). Des fouilles récentes ont permis la mise au jour de quelques vestiges humains néanderthaliens dans les niveaux moustériens J et I (David *et al.* 2007 ; Tillier *et al.* 2013). Lors de la campagne de 2012, deux molaires déciduales inférieures ont été découvertes dans la couche I, apportant de nouvelles informations sur les derniers artisans des industries du Paléolithique moyen dans le nord-est de la France. L'une des dents présente une lésion cervicale non carieuse de l'émail, inédite chez l'enfant, ce qui pose la question de son étiologie.

INDEX

Keywords: Arcy-sur-Cure, Grotte du Bison, Mousterian, Neanderthal, deciduous tooth, non-carious cervical lesion

Mots-clés: Arcy-sur-Cure, Grotte du Bison, Moustérien, Néanderthal, dent déciduale, lésion cervicale non carieuse

AUTHORS

ANNE-MARIE TILLIER

Université Bordeaux 1, UMR 5199 PACEA, Anthropologie des Populations Passées et Présentes, avenue des Facultés, FR-33405 Talence - am.tillier@pacea.u-bordeaux1.fr

MAURICE HARDY

UMR 7041, ArScAn, Laboratoire d'Ethnologie préhistorique, Maison René Ginouvès, 21 allée de l'Université, FR- 92023 Nanterre Cedex.

FRANCINE DAVID

UMR 7041, ArScAn, Laboratoire d'Ethnologie préhistorique, Maison René Ginouvès, 21 allée de l'Université, FR- 92023 Nanterre Cedex.

MICHEL GIRARD

342, Boulevard des Horizons, FR-06220 Vallauris

VLADIMIR D'IATCHENKO

Musei Anthropologii i Etnografii, Kunstkamera, Saint-Petersburg, Russie.